

Medical Director: Lindsay B. Hardy, M.D.

PROSTATE BIOPSY REPORT

 Patient: **Johnson, Thomas F.**

Age/Sex: 59/M

DOB: 01/01/1960

Phone#: 888.555.1212

MRN: 12345

 Physician: **Joseph Smith, M.D.**

ABC Urology Associates, Inc

1000 Main Street

Anytown, MA 12345

Referring Physician:

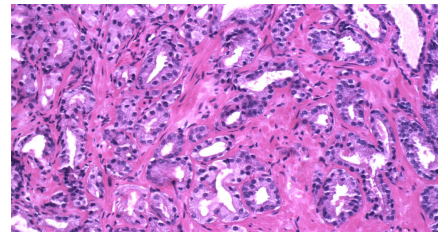
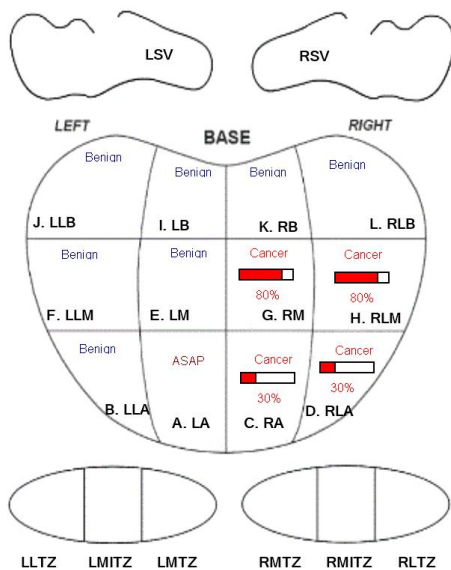
 Lab Case#: **SP19-00001**

Date Collected: 01/01/2019

Date Received: 01/01/2019

Date Reported: 01/02/2019

Accession#: QS19-00001

Diagnosis
Prostatic Adenocarcinoma


Adenocarcinoma; Gleason Score 6 (3+3)

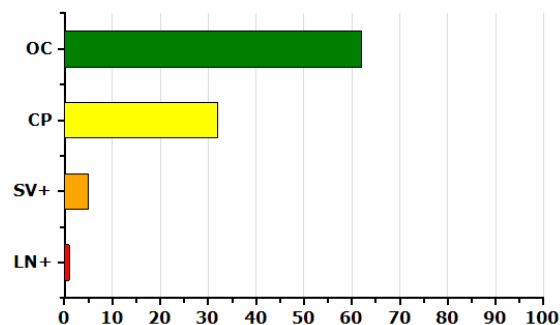
Partin Table

Gleason Score : 6(3+3)

Clinical Stage : T2b

PSA Range(ng/mL) : 6.001-10.0

Pathologic Stage	Percentage Score
Organ confined	62
Capsular Penetration	32
Seminal vesicle (+)	5
Lymph node (+)	1



This Partin Table was generated from clinically provided information. Stage T1c is assumed unless otherwise indicated. This data is extracted from the 2001 AUA abstract #952: Contemporary Update of Prostate Cancer Staging Nomograms (Partin Tables). Partin, Walsh, Epstein, Pearson. The statistical analysis of this data has not been determined or evaluated by VitalAxis.

Medical Director: Lindsay B. Hardy, M.D.

PROSTATE BIOPSY REPORT

Patient: Johnson, Thomas F.	Physician: Joseph Smith, M.D.	Lab Case#: SP19-00001
------------------------------------	--------------------------------------	------------------------------

Clinical Information

PSA: 6.50ng/ml ;

Diagnosis Summary
A. Left Apex: Focal Atypical Small Acinar Proliferation

B. Left Lateral Apex: Benign prostate tissue.

C. Right Apex: Adenocarcinoma; Gleason Score 6(3+3); Tumor measures 0.33 mm in length; 30% of the core involved by tumor; 1 of 1 core involved.; Perineural invasion not identified.Tumor is discontinuous

D. Right Lateral Apex: Adenocarcinoma; Gleason Score 6(3+3); Tumor measures 0.4 mm in length; 30% of the core involved by tumor; 1 of 1 core involved.; Perineural invasion not identified.Tumor is discontinuous

E. Left Mid: Benign prostate tissue.

F. Left Lateral Mid: Benign prostate tissue.

G. Right Mid: Adenocarcinoma; Gleason Score 6(3+3); Tumor measures 0.96 mm in length; 80% of the core involved by tumor; 1 of 1 core involved.; Perineural invasion not identified.

H. Right Lateral Mid: Adenocarcinoma; Gleason Score 6(3+3); Tumor measures 1.04 mm in length; 80% of the core involved by tumor; 1 of 1 core involved.; Perineural invasion not identified.

I. Left Base: Benign prostate tissue.

J. Left Lateral Base: Benign prostate tissue.

K. Right Base: Benign prostate tissue.

L. Right Lateral Base: Benign prostate tissue.

Gross Description
Diagnostic Description

Specimen	Pieces	Length (cm)	Diagnosis	Gleason Score	Involvement
A. Left Apex	1	1.2	ASAP		
B. Left Lateral Apex	1	1.4	Benign		
C. Right Apex	1	1.1	Adenocarcinoma	6(3+3)	30%
D. Right Lateral Apex	1	1.3	Adenocarcinoma	6(3+3)	30%
E. Left Mid	1	1.1	Benign		
F. Left Lateral Mid	1	1.2	Benign		
G. Right Mid	1	1.2	Adenocarcinoma	6(3+3)	80%
H. Right Lateral Mid	1	1.3	Adenocarcinoma	6(3+3)	80%
I. Left Base	1	1.0	Benign		
J. Left Lateral Base	1	1.0	Benign		
K. Right Base	1	1.2	Benign		
L. Right Lateral Base	1	1.2	Benign		

Due to loss of elastic tension and to formalin shrinkage, the measurements in the laboratory description may be less than those taken at the time of surgical removal.



 May Azar M.D.
 Final Report Electronically signed on 01/02/2019 at 12:00 PM