

Medical Director: Lindsay B. Hardy, M.D.

**PROSTATE BIOPSY REPORT**

 Patient: **Johnson, Thomas F.**

Age/Sex: 57/M

DOB: 01/01/1960

Phone#: 888.555.1212

MRN: 12345

 Physician: **Joseph Smith, M.D.**

ABC Urology Associates, Inc

1000 Main Street

Anytown, MA 12345

Referring Physician:

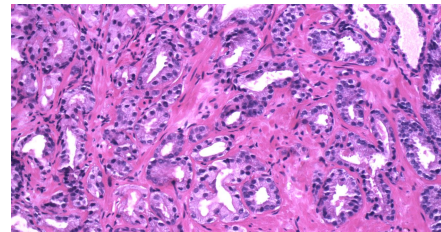
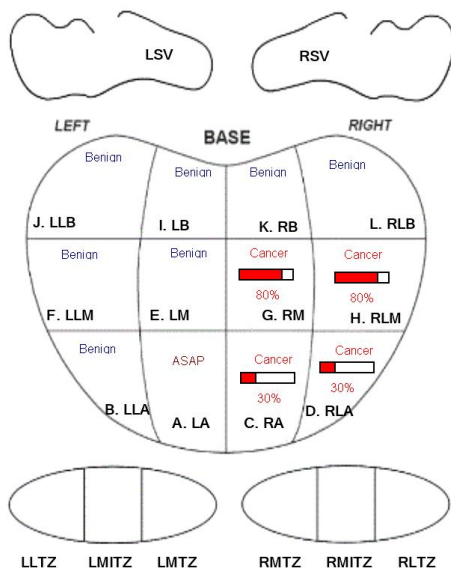
 Lab Case#: **SP17-00001**

Date Collected: 01/01/2017

Date Received: 01/01/2017

Date Reported: 01/02/2017

Accession#: QS17-00001

**Diagnosis**
**Prostatic Adenocarcinoma**


Adenocarcinoma; Gleason Score 6 (3+3)

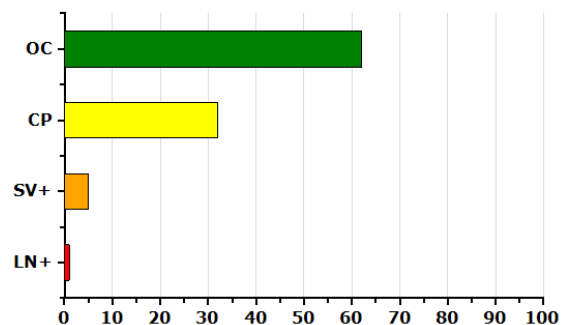
**Partin Table**

Gleason Score : 6(3+3)

Clinical Stage : T2b

PSA Range(ng/mL) : 6.001-10.0

Pathologic Stage	Percentage Score
Organ confined	62
Capsular Penetration	32
Seminal vesicle (+)	5
Lymph node (+)	1



This Partin Table was generated from clinically provided information. Stage T1c is assumed unless otherwise indicated. This data is extracted from the 2001 AUA abstract #952: Contemporary Update of Prostate Cancer Staging Nomograms (Partin Tables). Partin, Walsh, Epstein, Pearson. The statistical analysis of this data has not been determined or evaluated by VitalAxis.

Medical Director: Lindsay B. Hardy, M.D.

**PROSTATE BIOPSY REPORT**

Patient: <b>Johnson, Thomas F.</b>	Physician: <b>Joseph Smith, M.D.</b>	Lab Case#: <b>SP17-00001</b>
------------------------------------	--------------------------------------	------------------------------

**Clinical Information**

PSA: 6.50ng/ml ;

**Diagnosis Summary**
**A. Left Apex:** Focal Atypical Small Acinar Proliferation

**B. Left Lateral Apex:** Benign prostate tissue.

**C. Right Apex:** Adenocarcinoma; Gleason Score 6(3+3); Tumor measures 0.33 mm in length; 30% of the core involved by tumor; 1 of 1 core involved.; Perineural invasion not identified.Tumor is discontinuous

**D. Right Lateral Apex:** Adenocarcinoma; Gleason Score 6(3+3); Tumor measures 0.4 mm in length; 30% of the core involved by tumor; 1 of 1 core involved.; Perineural invasion not identified.Tumor is discontinuous

**E. Left Mid:** Benign prostate tissue.

**F. Left Lateral Mid:** Benign prostate tissue.

**G. Right Mid:** Adenocarcinoma; Gleason Score 6(3+3); Tumor measures 0.96 mm in length; 80% of the core involved by tumor; 1 of 1 core involved.; Perineural invasion not identified.

**H. Right Lateral Mid:** Adenocarcinoma; Gleason Score 6(3+3); Tumor measures 1.04 mm in length; 80% of the core involved by tumor; 1 of 1 core involved.; Perineural invasion not identified.

**I. Left Base:** Benign prostate tissue.

**J. Left Lateral Base:** Benign prostate tissue.

**K. Right Base:** Benign prostate tissue.

**L. Right Lateral Base:** Benign prostate tissue.

**Gross Description**
**Diagnostic Description**

Specimen	Pieces	Length (cm)	Diagnosis	Gleason Score	Involvement
A. Left Apex	1	1.2	ASAP		
B. Left Lateral Apex	1	1.4	Benign		
<b>C. Right Apex</b>	<b>1</b>	<b>1.1</b>	<b>Adenocarcinoma</b>	<b>6(3+3)</b>	<b>30%</b>
<b>D. Right Lateral Apex</b>	<b>1</b>	<b>1.3</b>	<b>Adenocarcinoma</b>	<b>6(3+3)</b>	<b>30%</b>
E. Left Mid	1	1.1	Benign		
F. Left Lateral Mid	1	1.2	Benign		
<b>G. Right Mid</b>	<b>1</b>	<b>1.2</b>	<b>Adenocarcinoma</b>	<b>6(3+3)</b>	<b>80%</b>
<b>H. Right Lateral Mid</b>	<b>1</b>	<b>1.3</b>	<b>Adenocarcinoma</b>	<b>6(3+3)</b>	<b>80%</b>
I. Left Base	1	1.0	Benign		
J. Left Lateral Base	1	1.0	Benign		
K. Right Base	1	1.2	Benign		
L. Right Lateral Base	1	1.2	Benign		



 May Azar M.D.  
 Final Report Electronically signed on 01/02/2017 at 12:00 PM