

Medical Director: Lindsay B. Hardy, MD.

Dermatopathology Report

Patient: Johnson, Thomas F. Age/Sex: 57/M DOB: 01/01/1960 Phone#: 888.555.1212 MRN:12345	Physician: Joseph Smith, M.D. ABC Dermatology Partners 1000 Main Street Anytown, MA 12345 Referring Physician: Referring Physician Fax:	Lab Case#: SP17-00001 Date Collected: 01/01/2017 Date Received: 01/01/2017 Date Reported: 01/02/2017 Accession#: QS17-00001
---	---	--

Clinical Information

ICD: L98.9

Diagnosis

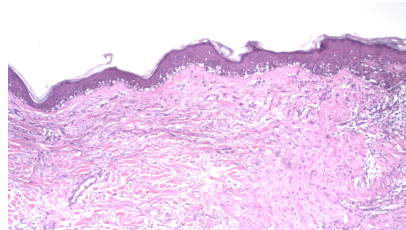
Right Posterior Upper Arm, Skin and Subcutis, Biopsy

BROAD MALIGNANT MELANOMA IN SITU, LARGELY HIGHLY NESTED, WITH FOCAL FEATURES OF JUNCTIONAL MELANOCYTIC NEVUS OF DYSPLASTIC TYPE (PERHAPS A PRE-EXISTING ONE), BOTH RESIDUAL AND RECURRENT, AROUND AND ABOVE HYPERTROPHIC SCAR OF PRIOR PROCEDURE; WIDELY AND COMPLETELY EXCISED.

COMMENTS:

There is no evidence of past or current dermal involvement by atypical melanocytes. This is a Tis (AJCC microstaging).

Images



*Residual Malignant Melanoma In Situ with
Contiguous Melanocytes and Adjacent Scar*

Gross Description

Site	Description
Right Posterior Upper Arm, Skin and Subcutis, Biopsy	Received in formalin with the patient's name labeled "Right Posterior Upper Arm" consists of 1 fragment of tan pigmented soft tissue measuring 3.5 x 1.5 x 0.4cm. The specimen is inked black and serially sectioned into 13 pieces. The tips are submitted in cassette 1 and the remaining sections are submitted in cassettes 2-5. Totally submitted in 5 cassettes.



Aldo Gonzalez-Serva M.D.
 Final Report Electronically signed on 01/02/2017 at 12:00 PM